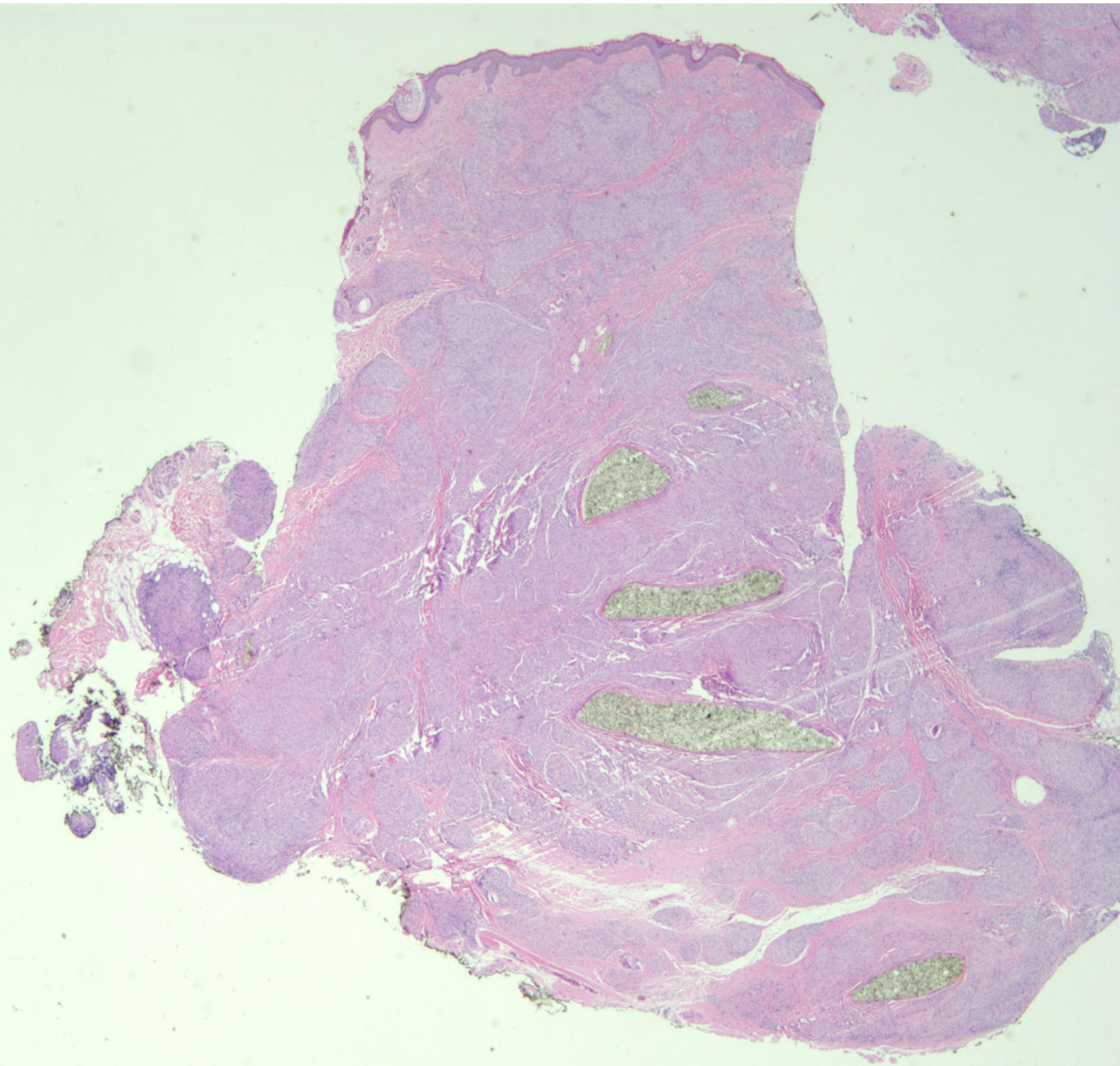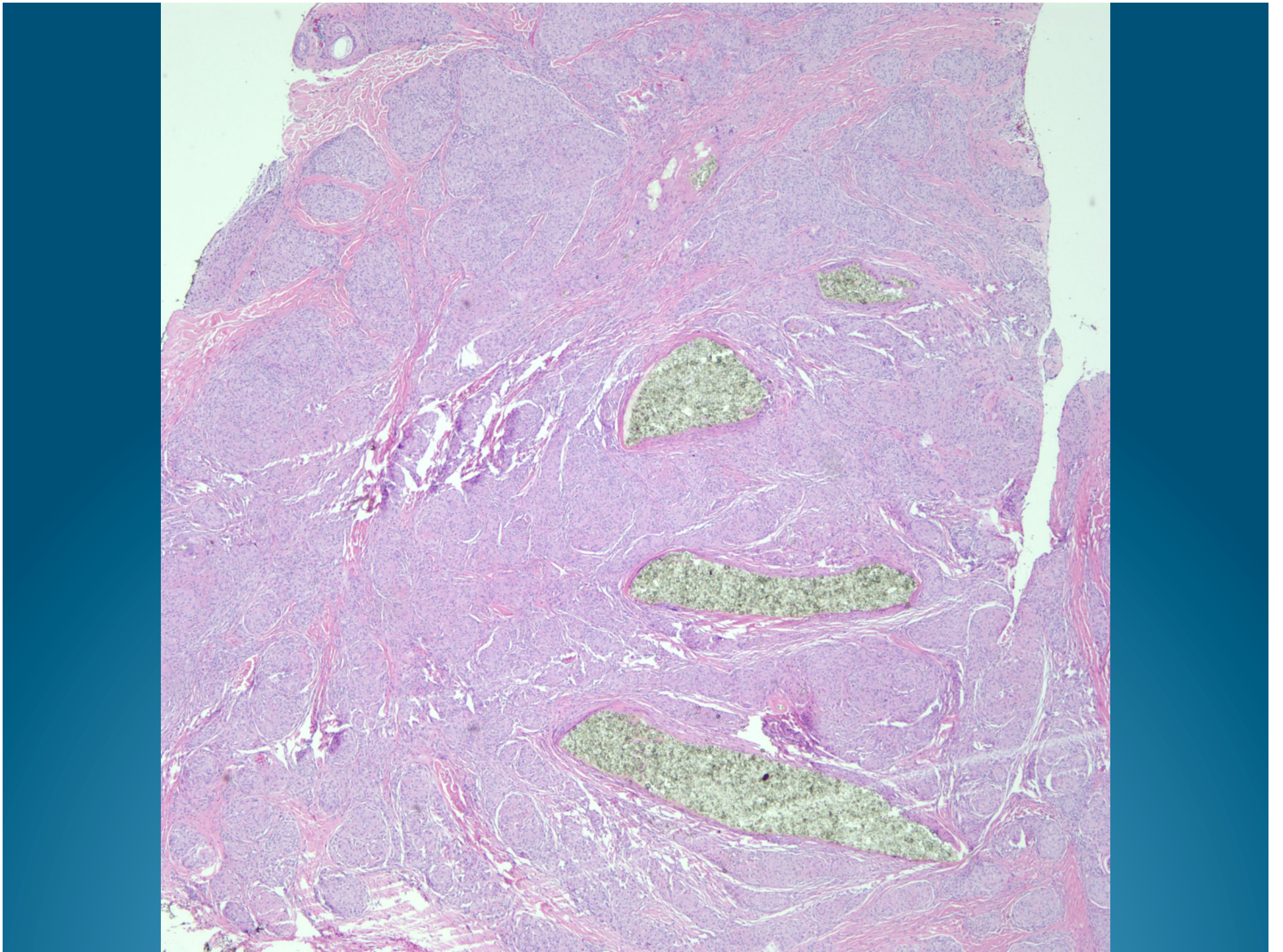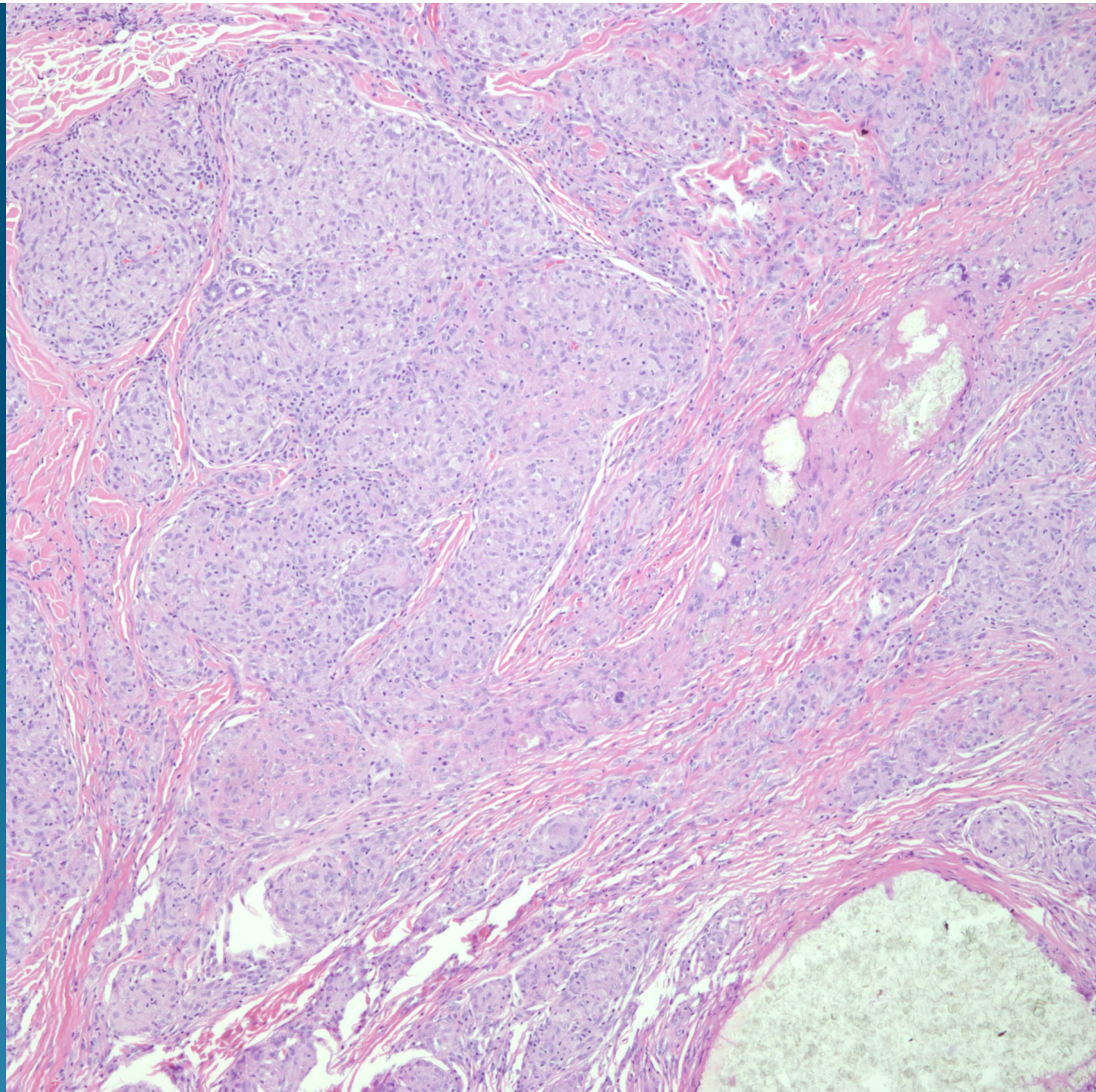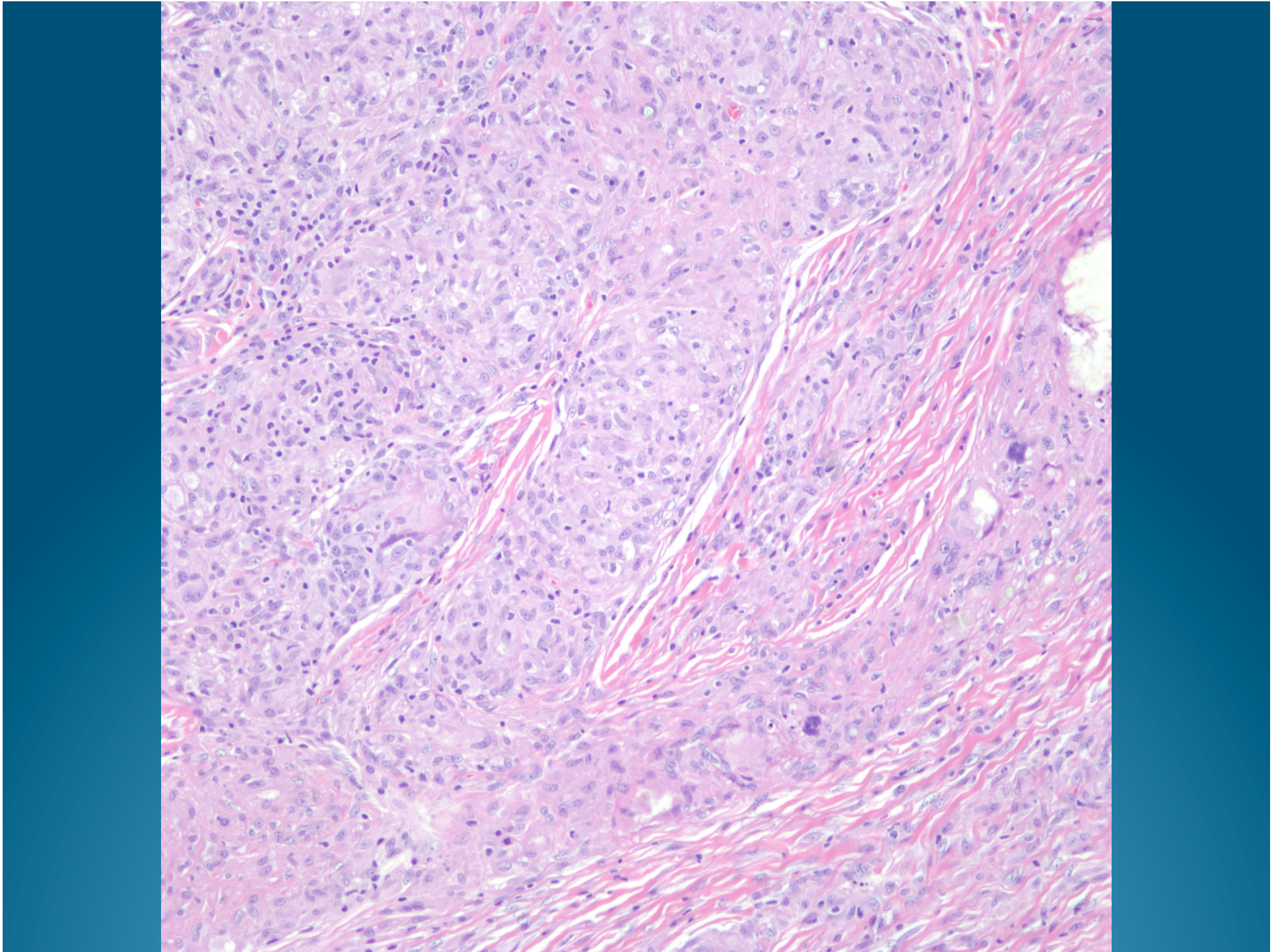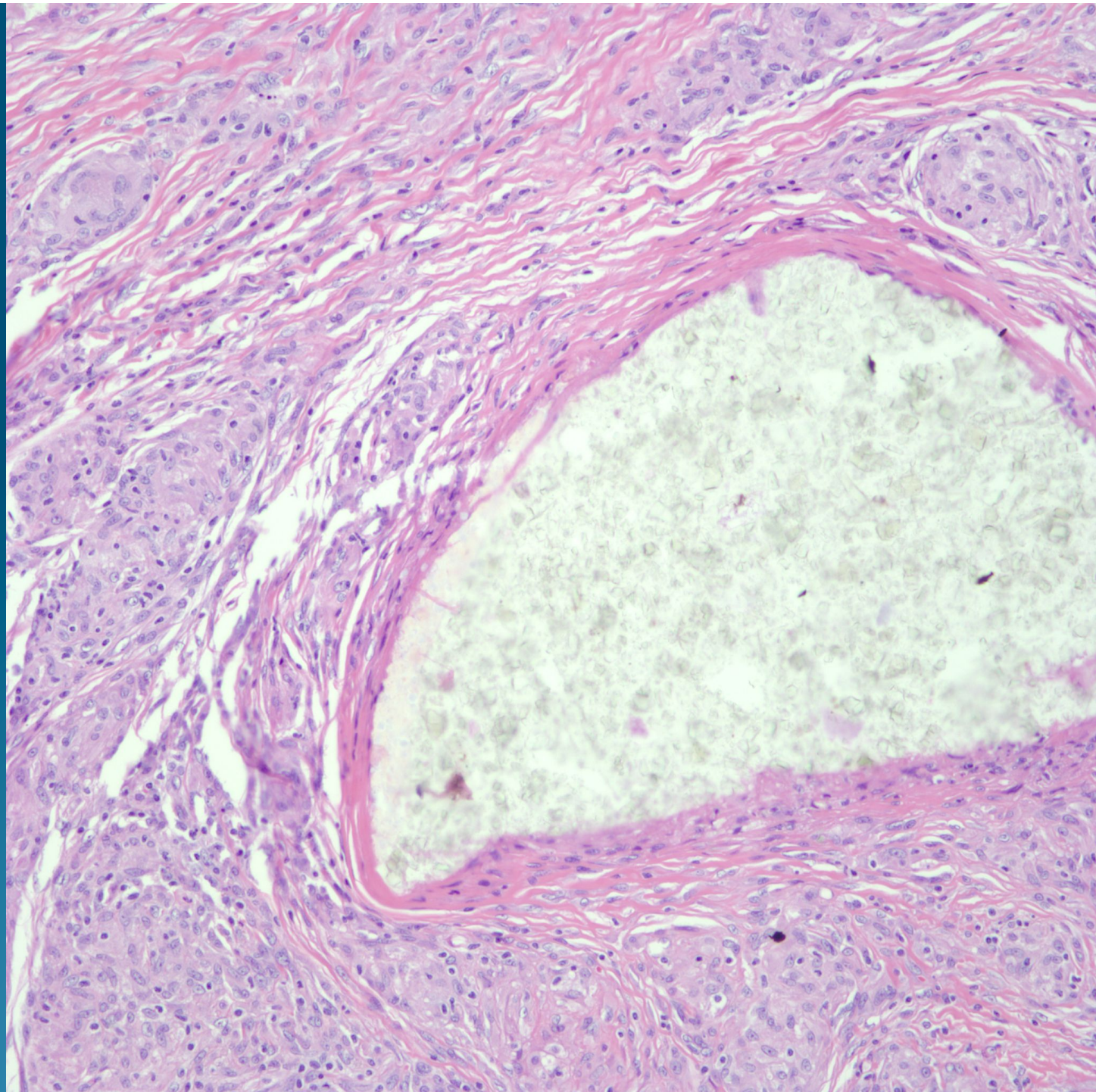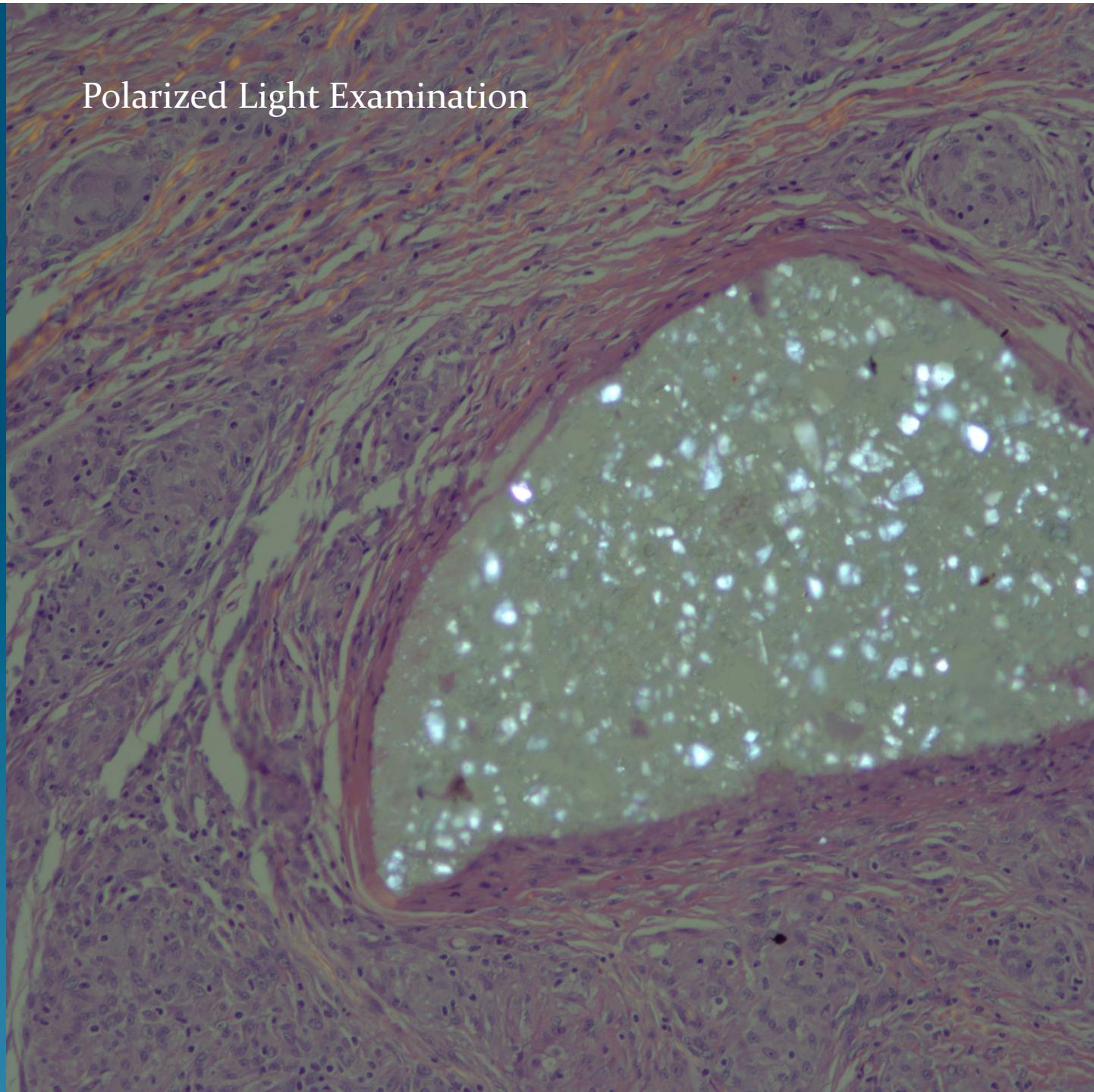




## Polarized Light Examination



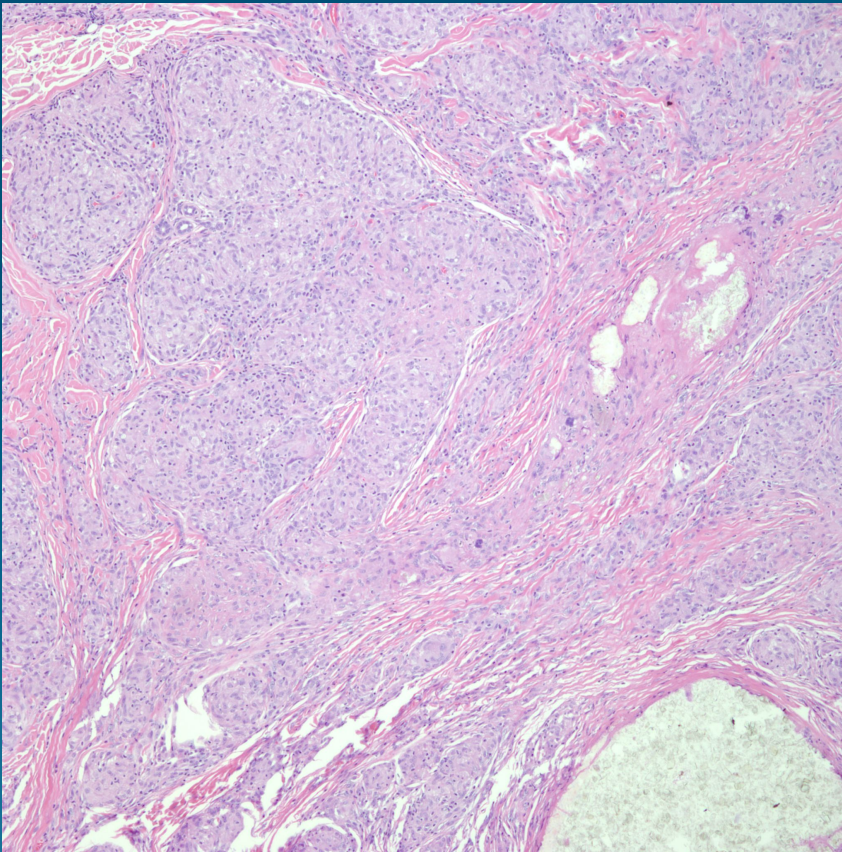
# What is the best diagnosis?

- A. Sarcoidal foreign body reaction
- B. Gouty tophus
- C. Giant cell tumor of tendon sheath
- D. Rheumatoid nodule
- E. Calcinosis cutis

# Sarcoidal foreign body reaction



# Pearls



- Sarcoidal granulomas with minimal associated chronic inflammation (naked granuloma)
- May be indistinguishable from sarcoidosis
- Get AFB, Fite, PAS to rule out Mycobacterial/fungal infection
- Always polarize to rule out foreign body
- NOTE: Finding a foreign body or tattoo does not exclude underlying sarcoidosis